Author Manuscript

Author Manuscript

Author Manuscript

Author Manuscript

HHS Public Access

Author manuscript

Clin Breast Cancer. Author manuscript; available in PMC 2024 December 01.

Published in final edited form as:

Clin Breast Cancer. 2023 December ; 23(8): 775–783. doi:10.1016/j.clbc.2023.04.004.

Metaplastic Breast Cancer: Current Understanding and Future Directions

Alexandra Thomas[1], **Emily Douglas**[1], **Jorge S. Reis-Filho**[2], **Metin N. Gurcan**[1], **Hannah Y. Wen**[2]

[1]Department of Internal Medicine, Wake Forest University School of Medicine, Winston-Salem, North Carolina

[2]Department of Pathology and Laboratory Medicine, Memorial Sloan Kettering Cancer Center, New York, NY, USA

Abstract

Metaplastic breast cancers (MBC) encompass a group of highly heterogeneous tumors which share the ability to differentiate into squamous, mesenchymal or neuroectodermal components. While often termed rare breast tumors, given the relatively high prevalence of breast cancer, they are seen with some frequency. Depending upon the definition applied, MBC represents 0.2%–1% of breast cancers diagnosed in the United States. Less is known about the epidemiology of MBC globally, though a growing number of reports are providing information on this. These tumors are often more advanced at presentation relative to breast cancer broadly. While more indolent subtypes exist, the majority of MBC subtypes are associated with inferior survival. MBC is most commonly of triple-negative phenotype. In less common hormone receptor positive MBCs, hormone receptor status appears not to be prognostic. In contrast, relatively rare HER2-positive MBCs are associated with superior outcomes. Multiple potentially targetable molecular features are overrepresented in MBC including DNA repair deficiency signatures and PIK3/AKT/mTOR and WNT pathways alterations. Data on the prevalence of targets for novel antibody-drug conjugates is also emerging. While chemotherapy appears to be less active in MBC than in other breast cancer subtypes, efficacy is seen in some MBCs. Disease-specific trials, as well as reports of exceptional responses, may provide clues for novel approaches to this often hard-to-treat breast cancer. Strategies which harness newer research tools, such as large data and artificial intelligence hold the promise of

Corresponding Author Alexandra Thomas, MD, Section of Hematology and Oncology, Wake Forest School of Medicine, 1 Medical Center Blvd, Winston-Salem, NC 27157 (Tel) 336-716-7217, althomas@wakehealth.edu.

Disclosure of Potential Conflicts of Interest

AT reports stock ownership: Johnson & Johnson, Gilead Sciences, Bristol Myers Squibb, Pfizer; consulting or advisory Role: BeyondSpring Pharmaceuticals, Lilly, Genentech, AstraZeneca; Research Funding: Sanofi (to the institution); royalties UpToDate; J.S.R.F reports receiving personal/consultancy fees from Goldman Sachs, Bain Capital, REPARE Therapeutics, Saga Diagnostics, Paige.AI and Swarm, membership of the scientific advisory boards of VolitionRx, REPARE Therapeutics and Paige.AI, membership of the Board of Directors of Grupo Oncoclinicas, and ad hoc membership of the scientific advisory boards of AstraZeneca, Merck, Daiichi Sankyo, Roche Tissue Diagnostics and Personalis; MNG is a paid consultant to Gilead Sciences; and a paid consultant, shareholder, and board member of Otologic Technologies; HYW reports advisory role for AstraZeneca.

Publisher's Disclaimer: This is a PDF file of an unedited manuscript that has been accepted for publication. As a service to our customers we are providing this early version of the manuscript. The manuscript will undergo copyediting, typesetting, and review of the resulting proof before it is published in its final form. Please note that during the production process errors may be discovered which could affect the content, and all legal disclaimers that apply to the journal pertain.

Author Manuscript Author Manuscript Author Manuscript Author Manuscript

overcoming historic barriers to the study of uncommon tumors and could markedly advance disease-specific understanding in MBC.

Keywords

metaplastic; rare; breast cancer

Introduction

Metaplastic breast cancers (MBCs) represent a highly heterogeneous group of breast tumors that are unified in the ability to differentiate into squamous, mesenchymal or neuroectodermal elements. These tumors are generally considered an aggressive subgroup of breast cancers and are often considered "rare" based on strict criteria.[1] Their incidence, however, is likely underestimated due to variability in making the diagnosis and to multiple overlapping diagnosis codes. Additionally, given the high prevalence of breast cancer overall, MBC is encountered with some frequency. Here we review current understanding of the epidemiology of this disease, as well as pathologic and molecular features of MBC, with a focus on how this might suggest therapeutic targets. We also review current and emerging treatment options and finally discuss how contemporary research tools could spur marked advances in disease-specific understanding of tumor type.

Epidemiology and Clinical Features

Discerning the incidence of MBC is complex due to both variability in making the diagnosis as well as to multiple possible diagnosis codes into which these tumors can be registered. For example, the International Classification of Disease for Oncology (ICD-O) has a code for MBC not otherwise specified (8575/3) within a broader range of complex epithelial neoplasms.[2] Depending upon the definition applied, MBCs represent 0.2%–1% of breast cancers diagnosed in the United States[1, 3–7].

Globally, the incidence of MBC is even more challenging to discern with more limited, if any, registry data in some regions. Acknowledging all the imperfections in cross-study comparisons, especially in registration of an uncommon tumor, collectively reviewing individual reports, can provide insight into the burden of this disease globally (Table 1).[6, 8–14] The definitions of MBC varied among these reports, though they generally used ICD-O 3rd edition or searching by terms such as "osseous and squamous". Across the globe, incidence ranged from 0.5–1.9% of breast cancers. Incidence of advanced disease at presentation appears higher in developing countries.

Median age at presentation is slightly older with MBC than with invasive ductal carcinoma not otherwise specified (NOS), with median age for patients with MBCs being 63 in two recent registry series.[3, 6] The incidence appears to be slightly higher in Blacks than in other racial groups.[3, 15] MBCs present more frequently with Stage II-IV disease on the basis of large tumor size or *de novo* metastatic disease than breast cancers of more common histologies.[4, 15] Axillary lymph node involvement is less common due to the propensity of these tumors to spread hematogenously rather than via the lymphatic system.[4, 15, 16] MBC is

Author Manuscript Author Manuscript Author Manuscript Author Manuscript

most commonly of triple-negative phenotype, though hormone receptor-positive and human epidermal receptor-2 (HER-2)-positive MBCs can represent a sizeable minority of these tumors.[3, 17, 18] These tumors can have features of aggressive disease on mammogram and magnetic resonance imaging with characteristic findings including irregular masses, high signal intensity on T2-weighted images, and non-circumscribed margins.[19–21]

Multiple studies have demonstrated inferior clinical outcomes for patients with MBC relative to both breast cancer broadly and triple-negative breast cancer.[3, 4, 17, 22] A recent large study found 5-year overall survival for patients with Stage I-III breast cancer to be 72.5% for those with MBC and 87.5% for those with non-MBC ($p<0.001$)[22]. When considering only triple-negative breast, 5-year overall survival was 71.1% with MBC and 77.8% for those with non-MBC ($p<0.001$). Another recent NCDB-based review reported a 90-day mortality of 2.3% with MBC.[23]

While most MBCs are aggressive and high grade, low risk histologies do exist and are important to identify; these include low grade adenosquamous and fibromatosis-like MBC (Figure 1).[7] The WHO Classification identifies four aggressive histologies within MBC: spindle cell carcinoma, squamous cell carcinoma, MBC with heterologous mesenchymal differentiation, and mixed MBCs (Figure 2).[7] Outcomes appear to vary by histology, with two recent large series finding superior survival for those with tumors with heterologous differentiation[24, 25] However, these reports differed with regard to which subtype had the poorest survival, possibly reflecting the different survival endpoints, study populations or the heterogeneity of MBC overall. One series with 132 patients found inferior survival with metaplastic squamous cell carcinomas[24] and the other series, with 364 patients, reported inferior clinical outcomes with spindle cell carcinomas.[25] A single institution review of 45 cases found inferior survival for those with mixed histology MBCs relative to other subtypes combined.[26] The large series which combined registry cases from Europe and Asia found superior overall survival for patients diagnosed with MBC in Asia relative to those diagnosed in Europe, though this difference did not persist when cases with locally advanced disease at presentation were excluded.[25]

Multiple series suggest that, unlike in invasive ductal carcinoma NOS, disease hormone receptor status is not prognostic in MBC.[3, 5, 27, 28] In contrast tumor HER2-positive status has been associated with survival matching that of patients with invasive ductal carcinoma NOS, possibly related to treatment with HER2-directed therapies.[3]

Molecular Features

Metaplastic breast carcinomas demonstrate characteristic patterns with regard to intrinsic subtype and triple-negative breast cancer subtype groupings. Most metaplastic breast carcinomas fall into either the claudin-low or basal-like intrinsic subtypes. A recent review from Memorial Sloan Kettering found that for 28 MBCs, those with a predominant spindle cell component were uniformly claudin low.[29] In this work, the triple-negative breast cancer subtypes most commonly identified were mesenchymal and basal-like; tumors with a predominant chondroid component were uniformly mesenchymal. Luminal androgen receptor and immunomodulatory subtypes were not identified in this analysis of 28 MBCs.

Author Manuscript Author Manuscript Author Manuscript Author Manuscript

Recent work which examined The Cancer Genome Atlas (TCGA) Pan-Cancer Atlas samples found that some MBCs may have non-breast predominate signatures.[30] This work analyzed the distribution of breast cancers with special histologies, including 14 MBCs according to the clustering of cluster assignments (CoCA) pan-cancer grouping. Most breast tumors fell into groups 20 or 23, which broadly correlate with basal-like or luminal breast cancers; this was the case with 7 of the MBC cases. The other 7 of the 14 MBCs had non-breast predominate signatures. Four of these tumors fell into groups 4 and 8, which are dominated by sarcomas and melanomas. All 4 of these MBCs had mesenchymal components. Three MBCs with predominate squamous differentiation clustered into group 8 which is typically associated with head and neck, cervical, lung and esophageal squamous cell carcinomas. Of note, TCGA pan-cancer analyses have found that some non-MBC basal-like breast tumors can show high correlation of mRNA expression patterns with lung squamous carcinomas.[31]

Genomic and transcriptomic analyses have found that MBCs have an over-representation of potential disease targets, including features of DNA repair deficiency, PIK3/AKT/mTOR and WNT pathways alterations.[32–35] These possible targets vary by predominate histologic component. In these analyses, there was significant heterogeneity among individual MBCs. Multiple studies have found a relatively high frequency of homologous repair deficiency signatures in MBCs.[35, 36] Whether this correlates with response to platinum agents or PARP inhibition in MBC has not been widely studied, although a single institution study reported that with median of 8.5 years of follow-up all 9 patients who received adjuvant platinum-based treatment for MBC were alive.[37] Limited information is also available on the rate of MBC in patients with germline *BRCA1, BRCA2* or *PALB2* mutations, although one recent study of over 3,200 patients found a higher rate of MBCs in patients with germline *BRCA1/BRCA2* mutations relative to those with wild-type *BRCA1/BRCA2* (3.2% vs 0.8%).[38]

Multiple studies have found that MBCs frequently express programmed death-ligand 1 (PD-L1).[39–41] A series from Memorial Sloan Kettering, which examined the PD-L1 status of 42 treatment naïve MBCs across a variety of PD-L1 platforms and cut-off criteria, found PD-L1 expression to be present in most MBCs and higher than the frequency expected in invasive ductal carcinomas NOS of triple-negative phenotype.[40] Examination of 82 MBCs from Taiwan examined PD-L1 expression, as well as tumor-infiltrating lymphocytes, another marker for disease vulnerability to immune therapy.[42] In this work overall 34.1% of tumors had intermediate or high stromal tumor infiltrating lymphocytes (TIL) (intermediate >10% to <60% and high ≥ 60% of immune cells in stromal tissue adjacent to the tumor) and 47.6% of immune cells and 17.1% of tumor cells exhibited ≥ 1% PD-L1 positivity. In this series multivariate analyses found that intermediate or high TILS, but not PD-L1 positivity correlated with improved clinical outcomes.

Data are emerging on molecular features of MBCs which may suggest responsiveness to antibody-drug conjugates. One recent study reported a rate of at least 8.4% of HER2-low testing results in MBCs on the basis of immunohistochemical HER2 staining of either 1+ or 2+ with negative in-situ hybridization results, suggesting possible vulnerability to HER2-low directed antibody-drug conjugate therapy.[10] In this work, 31% of MBCs were reported as HER2 negative without further details available on testing results. Another series found

Author Manuscript Author Manuscript Author Manuscript Author Manuscript

32% of high-grade MBCs to be HER2-low, with all of these tumors being HER2 1+ and none found to be HER2 2+.[43] This study of 65 tumors also found 85% of these tumors to be TROP2 positive, with 80% of these exhibiting greater than 10% TROP2-positivity and with 98% of tumors with squamous differentiation being TROP2- positive.[43] Higher levels of TROP2 expression have been associated with great efficacy of sacituzumab govetecan[44] and TROP2 is increasingly emerging as a promising therapeutic target in breast oncology.[45] While promising, the degree of responsiveness of MBCs, which have intra- and inter-tumor heterogeneity, to antibody-drug conjugate approaches remains largely unknown.

Therapeutic Approaches

Mainstay approaches to breast cancer appear to have some efficacy in MBC, though typically at rates lower than that seen with triple-negative breast cancer broadly. While significantly less common than in triple-negative breast cancer NOS, pathologic complete responses to neoadjuvant therapy, characterized primarily by chemotherapy, are seen in MBC at rates of 0–10% in single-institution or database series (Figure 3).[13, 28, 46–48] Response rates to chemotherapy in palliative settings were 8.3% in one series, lower than what we commonly see for triple-negative breast cancers NOS;[49] though multiple large registry series suggest improved outcomes with chemotherapy relative to no chemotherapy. Similarly, studies also suggest benefit to radiation over no radiation.[17, 23, 50, 51] While hormone receptor status is not prognostic in most MBC series, at least one recent large series suggest improved outcomes with anti-estrogen therapy, relative to no anti-estrogen therapy.[23] Tumor HER2-positive status has been associated with improved survival in MBC, likely on the basis of receipt of HER2-directed therapy.[3] Of note, the level of data supporting these approaches in MBC is not as robust as that commonly utilized for triple-negative breast cancer NOS, as in MBC available data are largely retrospective, come from series which are small and extend to earlier therapeutic eras and likely do not account for the marked heterogeneity of MBC.

Several trials which provide disease-specific results have been completed in MBC. A Phase I study conducted at MD Anderson Cancer Center looked at activity in mesenchymal MBC of mTOR inhibition combined with liposomal doxorubicin and bevacizumab.[52] The investigators hypothesized that targeting the PI3K and related pathways could enhance tumor response to chemotherapy and accrued 52 patients at a single center over 5.5 years. The objective response rate was 21%, with responses more likely to occur in those with tumors with pathway aberrations. Another clinical trial success in MBC comes from cohort 36 of the DART trial, which offered combination nivolumab and ipilimumab, to patients across a large range of baskets of rare tumors.[53] Cohort 36 studied patients with MBC and rapidly completed accrual. Of 17 evaluable patients, 3 had on-going responses at 27, 25 and 23 months. Notably, responses were observed in patients without the traditional biomarkers for response to immune therapy, with responses seen in tumors with low tumor mutational burden, low PD-L1, and absent TILs. The Artemis trial looked at neoadjuvant therapy in triple-negative breast cancers and prospectively identified a subset of 39 patients with MBC.[54] Patients received neoadjuvant doxorubicin and cyclophosphamide for two cycles followed by on-treatment, imaging-based response assessment. Responders continued to receive standard of care therapy, while non-responders received tumor targeted therapy

Author Manuscript Author Manuscript Author Manuscript Author Manuscript

based on on-study biopsies. Artemis reported a pathologic complete response rate in MBC of 23%. It demonstrated that those who achieved a pathologic complete response had improved survival outcomes, comparable to that seen in triple-negative breast cancer NOS. A similar correlation between pathologic complete response and survival outcomes in MBC was also recently reported in a review utilizing the National Cancer Database.[48]

Reports of exceptional response are increasingly observed and may also suggest disease vulnerabilities in MBC. Responses have been observed across a wide spectrum of agent classes as well as across a spectrum of metaplastic histologic subtypes, again pointing to the heterogeneity of the disease (Table 2).[53, 55–60] Understanding individual tumor vulnerability to a specific therapy may be part of the complex puzzle of improving outcomes in MBC, though more ubiquitous targets such as TROP2 or HER2 suggest that there could be approaches that may have broader efficacy, including approaches which capitalize on bystander effect as seen in HER2-low disease.[61, 62]

Future Directions

Conducting clinical trials in MBC and uncommon tumors has been challenging for a variety of reasons. The relatively small number of patients with these tumors makes it challenging for individual sites to open and operate trials that enroll only occasional patients, and raise concerns about statistical validity with a limited study size.[63] Further, while promising new therapeutic agents are likely central to advances in this space, a smaller treatment population may make such studies less attractive to commercial stakeholders.[64] Despite the barriers, there have been successes within the National Cancer Institute's National Clinical Trials Network, including the recent basket trial approach used by the DART trial[53] and well as a series of trials conducted by NRG (legacy GOG) in rare gynecologic tumors.[65] Additionally, the recent recognition that a sizeable portion of cancers are rare and associated with inferior outcomes[1], possibly due to less research in this area, has led to momentum around enhancing infrastructure to study these tumors, including through international collaborations.[66]

Within the established paradigm of clinical trials, opportunities may exist to gain disease-specific information in MBC and other uncommon breast cancers. Many trials, particularly those looking at triple-negative breast cancer, allowed enrollment of patients with MBC, but did not prospectively identify these patients. Retrospective review to identify these patients could provide valuable, even randomized information. As these trials are often enriched for high-risk triple-negative breast cancer, they may have a sizeable number of patients with MBC. Though challenges include the degree to which specific histology was consistently collected in these often, international studies. A more promising option could be to prospectively identify patients with MBC as we open new studies or move forward with platform trials. This would allow for full cohort outcome analyses as well as preplanned analyses on responses in less common tumors such as MBC (Figure 4). Modern technology, including digital pathology, should make this less costly and more feasible than in earlier eras[67], and with dedicated resources, could allow for upfront central review of uncommon breast tumors. As questions in uncommon tumors are less likely to be addressed by commercial stakeholders, and as costs for prospective identification and

Author Manuscript Author Manuscript Author Manuscript Author Manuscript

validation may decrease, could this become a role for federally supported clinical trials? As virtual pathology transcends borders and perhaps would have a relatively light regulatory burden, could prospective pathology review be incorporated into international studies?

Finally, rapidly emerging technologic tools, real world evidence and artificial intelligence, which will likely advance care delivery, have particular promise for obtaining valuable disease-specific information in MBC and other uncommon cancers. The US Food and Drug Administration and other stakeholders are increasingly recognizing that real world data can have applications in rare diseases, when clinical trials are impractical.[68, 69] At one level real world data could provide retrospective information on outcomes of patients with MBC, which could offer larger and more contemporary datasets than what has historically been available. The "virtual trial" paradigm, however, could hold even more promise. In this model, centralized retrospective data collected from the electronic health record would be integrated with prospective intentional data capture during select study periods.[70] Privacy concerns would need to be addressed and consent may be required for portions of this work. One example of intentional data capture could be outcomes for patients with HER2-low metaplastic breast cancer who receive antibody-drug conjugate therapy. This tool would likely be used with lower risk interventions. As a powerful tool to study patients with MBC where they are receiving their care this could bring us more meaningful information than we have had in the past and could expand study access and overcome barriers inherent with small population sizes. Further, this approach has the promise of global applications.

An arguably futuristic approach would incorporate artificial intelligence. Many of the prior applications of artificial intelligence for breast cancer were designed and implemented for breast cancer in general both in radiology and pathology.[71–74] These applications may be customized for MBC. For instance, for MBC specifically, one application would be to validate deep learning algorithms to diagnose and subclassify MBCs[75], which could be subsequently electronically incorporated into the medical record and utilized to identify patients with MBC. This would allow for the reliable grouping of cohorts of patients with MBC as well as of cohorts with other rare breast tumors (Figure 5). These cohorts could then be studied for outcomes either with observation or with prespecified interventions. Such a design would improve our confidence in the tumor types represented in a cohort as well as reduce registration issues and interobserver variability, which constitute significant challenges for the study of MBC and other uncommon breast cancers. Such an approach could also eventually have global applications. Another application would be to generate histopathological images of MBC artificially to help with development of novel algorithms to minimize the impact of small number of cases.[76] Such approaches may enable us to analyze the relationship between MBC characteristics and several biomarkers quantitatively.[74]

Conclusions

MBC is seen with some frequency in clinical practice. Prognosis for this subtype of breast cancer is currently inferior to that of most other breast cancers, though enhanced molecular understanding of MBC and newer therapeutic options provide reason for optimism. Additionally, newer research tools which harness technology could rapidly further disease-

Author Manuscript Author Manuscript Author Manuscript Author Manuscript

specific understanding including artificial intelligence which can be deployed to study MBC. Leveraging these advances, on multiple fronts, holds promise to markedly improve outcomes for patients with MBC in the coming years.

Acknowledgements

AT is supported by the Williams Family Chair in Breast Oncology. JSR-F is funded in part by the NIH/NCI P50 CA247749 01 grant, by the Breast Cancer Research Foundation and by Susan G Komen. HW is supported in part by a National Institutes of Health/National Cancer Institute Cancer Center Support Grant (P30CA008748)

References:

1. DeSantis CE, Kramer JL, Jemal A. The burden of rare cancers in the United States. CA: a cancer journal for clinicians. 2017;67:261–272. [PubMed: 28542893]
2. Fritz AG. International classification of diseases for oncology : ICD-O. Third edition, First revision. ed. Geneva: World Health Organization; 2013.
3. Schroeder MC, Rastogi P, Geyer CE Jr., Miller LD, Thomas A. Early and Locally Advanced Metaplastic Breast Cancer: Presentation and Survival by Receptor Status in Surveillance, Epidemiology, and End Results (SEER) 2010–2014. The oncologist. 2018;23:481–488. [PubMed: 29330212]
4. Nelson RA, Guye ML, Luu T, Lai LL. Survival outcomes of metaplastic breast cancer patients: results from a US population-based analysis. Annals of surgical oncology. 2015;22:24–31. [PubMed: 25012264]
5. Paul Wright G, Davis AT, Koehler TJ, Melnik MK, Chung MH. Hormone receptor status does not affect prognosis in metaplastic breast cancer: a population-based analysis with comparison to infiltrating ductal and lobular carcinomas. Annals of surgical oncology. 2014;21:3497–3503. [PubMed: 24838367]
6. Mills MN, Yang GQ, Oliver DE, et al. Histologic heterogeneity of triple negative breast cancer: A National Cancer Centre Database analysis. European journal of cancer. 2018;98:48–58. [PubMed: 29870876]
7. Board WCoTE. Breast Tumours. Vol 2. 5 ed. Lyon, France: International Agency for Research on Cancer; 2019.
8. Jung SY, Jung KW, Ha J, et al. Different Patterns of Conditional Survival of Breast Cancer Patients by Age and Histologic Types: Evidence from the Korean Nationwide Registry. Cancer epidemiology, biomarkers & prevention : a publication of the American Association for Cancer Research, cosponsored by the American Society of Preventive Oncology. 2019;28:1169–1176.
9. Erjan A, Almasri H, Abdel-Razeq H, et al. Metaplastic Breast Carcinoma: Experience of a Tertiary Cancer Center in the Middle East. Cancer Control. 2021;28:10732748211004889. [PubMed: 33827281]
10. Bonadio RC, Costa FA, Mendes SV, et al. Disease Behavior and Treatment Response of Special Histological Types of Triple-Negative Breast Cancer. Clinical breast cancer. 2022;22:e892–e900. [PubMed: 36130851]
11. Samoon Z, Beg M, Idress R, Jabbar AA. Survival and treatment outcomes of metaplastic breast carcinoma: Single tertiary care center experience in Pakistan. Indian J Cancer. 2019;56:124–129. [PubMed: 31062730]
12. Sanges F, Floris M, Cossu-Rocca P, et al. Histologic subtyping affecting outcome of triple negative breast cancer: a large Sardinian population-based analysis. BMC cancer. 2020;20:491. [PubMed: 32487046]
13. Damera VV, Chowdhury Z, Tripathi M, Singh R, Verma RK, Jain M. Clinicopathologic Features of Metaplastic Breast Carcinoma: Experience From a Tertiary Cancer Center of North India. Cureus. 2022;14:e28978. [PubMed: 36237767]
14. Akrami M, Arasteh P, Mokhtari M, et al. Does metaplastic breast carcinoma demonstrate a different clinicopathological behavior in our region: The Shiraz Breast Cancer Registry. The breast journal. 2019;25:157–159. [PubMed: 30592108]

Author Manuscript Author Manuscript Author Manuscript Author Manuscript

15. Pezzi CM, Patel-Parekh L, Cole K, Franko J, Klimberg VS, Bland K. Characteristics and treatment of metaplastic breast cancer: analysis of 892 cases from the National Cancer Data Base. Annals of surgical oncology. 2007;14:166–173. [PubMed: 17066230]
16. Luini A, Aguilar M, Gatti G, et al. Metaplastic carcinoma of the breast, an unusual disease with worse prognosis: the experience of the European Institute of Oncology and review of the literature. Breast cancer research and treatment. 2007;101:349–353. [PubMed: 17009109]
17. Moreno AC, Lin YH, Bedrosian I, Shen Y, Babiera GV, Shaitelman SF. Outcomes after Treatment of Metaplastic Versus Other Breast Cancer Subtypes. J Cancer. 2020;11:1341–1350. [PubMed: 32047541]
18. Reis-Filho JS, Milanezi F, Steele D, et al. Metaplastic breast carcinomas are basal-like tumours. Histopathology. 2006;49:10–21. [PubMed: 16842242]
19. Wang S, Lou J, Zou Q, Jiang Y, Wang S, Shi H. Metaplastic Carcinoma of the Breast: MRI Features with Clinical and Histopathologic Correlation. Academic radiology. 2022.
20. Kong QC, Tang WJ, Chen SY, et al. Nomogram for the prediction of triple-negative breast cancer histological heterogeneity based on multiparameter MRI features: A preliminary study including metaplastic carcinoma and non- metaplastic carcinoma. Frontiers in oncology. 2022;12:916988. [PubMed: 36212484]
21. Langlands F, Cornford E, Rakha E, et al. Imaging overview of metaplastic carcinomas of the breast: a large study of 71 cases. The British journal of radiology. 2016;89:20140644. [PubMed: 27245135]
22. Ong CT, Campbell BM, Thomas SM, et al. Metaplastic Breast Cancer Treatment and Outcomes in 2500 Patients: A Retrospective Analysis of a National Oncology Database. Annals of surgical oncology. 2018;25:2249–2260. [PubMed: 29855830]
23. Elimimian EB, Samuel TA, Liang H, Elson L, Bilani N, Nahleh ZA. Clinical and Demographic Factors, Treatment Patterns, and Overall Survival Associated With Rare Triple-Negative Breast Carcinomas in the US. JAMA Netw Open. 2021;4:e214123. [PubMed: 33844001]
24. Tadros AB, Sevilimedu V, Giri DD, Zabor EC, Morrow M, Plitas G. Survival Outcomes for Metaplastic Breast Cancer Differ by Histologic Subtype. Annals of surgical oncology. 2021;28:4245–4253. [PubMed: 33389291]
25. Rakha EA, Tan PH, Varga Z, et al. Prognostic factors in metaplastic carcinoma of the breast: a multi-institutional study. British journal of cancer. 2015;112:283–289. [PubMed: 25422911]
26. Cimino-Mathews A, Verma S, Figueroa-Magalhaes MC, et al. A Clinicopathologic Analysis of 45 Patients With Metaplastic Breast Carcinoma. American journal of clinical pathology. 2016;145:365–372. [PubMed: 27124919]
27. Abada E, Kim S, Dozier K, et al. Estrogen receptor status has no prognostic relevance in metaplastic breast carcinoma. Cancer Treat Res Commun. 2022;33:100630. [PubMed: 36058202]
28. Al-Hilli Z, Choong G, Keeney MG, et al. Metaplastic breast cancer has a poor response to neoadjuvant systemic therapy. Breast cancer research and treatment. 2019;176:709–716. [PubMed: 31119569]
29. Weigelt B, Ng CK, Shen R, et al. Metaplastic breast carcinomas display genomic and transcriptomic heterogeneity [corrected]. Mod Pathol. 2015;28:340–351. [PubMed: 25412848]
30. Thennavan A, Beca F, Xia Y, et al. Molecular analysis of TCGA breast cancer histologic types. Cell Genom. 2021;1.
31. Cancer Genome Atlas N Comprehensive molecular portraits of human breast tumours. Nature. 2012;490:61–70. [PubMed: 23000897]
32. Piscuoglio S, Ng CKY, Geyer FC, et al. Genomic and transcriptomic heterogeneity in metaplastic carcinomas of the breast. NPJ Breast Cancer. 2017;3:48. [PubMed: 29214215]
33. Dieci MV, Smutna V, Scott V, et al. Whole exome sequencing of rare aggressive breast cancer histologies. Breast cancer research and treatment. 2016;156:21–32. [PubMed: 26907767]
34. Gonzalez-Martinez S, Perez-Mies B, Carretero-Barrio I, et al. Molecular Features of Metaplastic Breast Carcinoma: An Infrequent Subtype of Triple Negative Breast Carcinoma. Cancers. 2020;12. [PubMed: 33375055]
35. Moukarzel LA, Ferrando L, Da Cruz Paula A, et al. The genetic landscape of metaplastic breast cancers and uterine carcinosarcomas. Mol Oncol. 2021;15:1024–1039. [PubMed: 33021035]

Author Manuscript Author Manuscript Author Manuscript Author Manuscript

36. Ng CKY, Piscuoglio S, Geyer FC, et al. The Landscape of Somatic Genetic Alterations in Metaplastic Breast Carcinomas. Clinical cancer research : an official journal of the American Association for Cancer Research. 2017;23:3859–3870. [PubMed: 28153863]
37. Harper NW, Hodges KB, Stewart RL, et al. Adjuvant Treatment of Triple-Negative Metaplastic Breast Cancer With Weekly Paclitaxel and Platinum Chemotherapy: Retrospective Case Review From a Single Institution. Clinical breast cancer. 2019;19:e495–e500. [PubMed: 31208874]
38. Rodríguez-Fernández VC-CL, Valdés-Pons J, Castro-Parga GJD, Figueiredo-Alonso E, et al. New criteria to select patients with breast cancer to perform germline BRCA1/2 testing. Clin Obstet Gynecol Reprod Med. 2021;7.
39. Joneja U, Vranic S, Swensen J, et al. Comprehensive profiling of metaplastic breast carcinomas reveals frequent overexpression of programmed death-ligand 1. J Clin Pathol. 2016.
40. Grabenstetter A, Jungbluth AA, Frosina D, et al. PD-L1 Expression in Metaplastic Breast Carcinoma Using the PD-L1 SP142 Assay and Concordance Among PD-L1 Immunohistochemical Assays. The American journal of surgical pathology. 2021;45:1274–1281. [PubMed: 34115674]
41. Salisbury T, Abozina A, Zhang C, et al. Histological subtype is associated with PD-L1 expression and CD8+ T-cell infiltrates in triple-negative breast carcinoma. Ann Diagn Pathol. 2022;57:151901. [PubMed: 35091156]
42. Lien HC, Lee YH, Chen IC, et al. Tumor-infiltrating lymphocyte abundance and programmed death-ligand 1 expression in metaplastic breast carcinoma: implications for distinct immune microenvironments in different metaplastic components. Virchows Archiv : an international journal of pathology. 2021;478:669–678. [PubMed: 33089401]
43. Chartier S, Brochard C, Martinat C, et al. TROP2, androgen receptor, and PD-L1 status in histological subtypes of high-grade metaplastic breast carcinomas. Histopathology. 2022.
44. Bardia A, Hurvitz SA, Tolaney SM, et al. Sacituzumab Govitecan in Metastatic Triple-Negative Breast Cancer. The New England journal of medicine. 2021;384:1529–1541. [PubMed: 33882206]
45. Sakach E, Sacks R, Kalinsky K. Trop-2 as a Therapeutic Target in Breast Cancer. Cancers. 2022;14. [PubMed: 36612015]
46. Hennessy BT, Giordano S, Broglio K, et al. Biphasic metaplastic sarcomatoid carcinoma of the breast. Annals of oncology : official journal of the European Society for Medical Oncology / ESMO. 2006;17:605–613.
47. Wong W, Brogi E, Reis-Filho JS, et al. Poor response to neoadjuvant chemotherapy in metaplastic breast carcinoma. NPJ Breast Cancer. 2021;7:96. [PubMed: 34294707]
48. Haque W, Verma V, Schwartz MR, et al. Neoadjuvant Chemotherapy for Metaplastic Breast Cancer: Response Rates, Management, and Outcomes. Clinical breast cancer. 2022;22:e691–e699. [PubMed: 35193807]
49. Chen IC, Lin CH, Huang CS, et al. Lack of efficacy to systemic chemotherapy for treatment of metaplastic carcinoma of the breast in the modern era. Breast cancer research and treatment. 2011;130:345–351. [PubMed: 21792625]
50. Li Y, Chen M, Pardini B, Dragomir MP, Lucci A, Calin GA. The role of radiotherapy in metaplastic breast cancer: a propensity score-matched analysis of the SEER database. Journal of translational medicine. 2019;17:318. [PubMed: 31547814]
51. Trapani D, Giugliano F, Uliano J, et al. Benefit of adjuvant chemotherapy in patients with special histology subtypes of triple-negative breast cancer: a systematic review. Breast cancer research and treatment. 2021;187:323–337. [PubMed: 34043122]
52. Basho RK, Gilcrease M, Murthy RK, et al. Targeting the PI3K/AKT/mTOR Pathway for the Treatment of Mesenchymal Triple-Negative Breast Cancer: Evidence From a Phase 1 Trial of mTOR Inhibition in Combination With Liposomal Doxorubicin and Bevacizumab. JAMA Oncol. 2016.
53. Adams S, Othus M, Patel SP, et al. A Multicenter Phase II Trial of Ipilimumab and Nivolumab in Unresectable or Metastatic Metaplastic Breast Cancer: Cohort 36 of Dual Anti-CTLA-4 and Anti-PD-1 Blockade in Rare Tumors (DART, SWOG S1609). Clinical cancer research : an official journal of the American Association for Cancer Research. 2022;28:271–278. [PubMed: 34716198]
54. Yam C, Abuhadra N, Sun R, et al. Molecular Characterization and Prospective Evaluation of Pathologic Response and Outcomes with Neoadjuvant Therapy in Metaplastic Triple-Negative

Author Manuscript Author Manuscript Author Manuscript Author Manuscript

Breast Cancer. Clinical cancer research : an official journal of the American Association for Cancer Research. 2022;28:2878–2889. [PubMed: 35507014]

55. Gorshein E, Matsuda K, Riedlinger G, et al. Durable Response to PD1 Inhibitor Pembrolizumab in a Metastatic, Metaplastic Breast Cancer. Case Rep Oncol. 2021;14:931–937. [PubMed: 34248561]
56. Al Sayed AD, Elshenawy MA, Tulbah A, Al-Tweigeri T, Ghebeh H. Complete Response of Chemo-Refractory Metastatic Metaplastic Breast Cancer to Paclitaxel-Immunotherapy Combination. Am J Case Rep. 2019;20:1630–1635. [PubMed: 31690713]
57. Litton JK, Scoggins ME, Hess KR, et al. Neoadjuvant Talazoparib for Patients With Operable Breast Cancer With a Germline BRCA Pathogenic Variant. J Clin Oncol. 2020;38:388–394. [PubMed: 31461380]
58. Zhou N, Liu C, Hou H, et al. Response to apatinib in chemotherapy-failed advanced spindle cell breast carcinoma. Oncotarget. 2016;7:72373–72379. [PubMed: 27738308]
59. Yang MH, Chen IC, Lu YS. PI3K inhibitor provides durable response in metastatic metaplastic carcinoma of the breast: A hidden gem in the BELLE-4 study. J Formos Med Assoc. 2019;118:1333–1338. [PubMed: 30577988]
60. Seo T, Noguchi E, Yoshida M, et al. Response to Dabrafenib and Trametinib of a Patient with Metaplastic Breast Carcinoma Harboring a BRAF V600E Mutation. Case Rep Oncol Med. 2020;2020:2518383. [PubMed: 32206360]
61. Dave B, Gonzalez DD, Liu ZB, et al. Role of RPL39 in Metaplastic Breast Cancer. Journal of the National Cancer Institute. 2017;109.
62. Modi S, Gambhire D, Cameron D. Trastuzumab Deruxtecan in HER2-Low Breast Cancer. Reply. The New England journal of medicine. 2022;387:1145–1146. [PubMed: 36130006]
63. Casali PG, Bruzzi P, Bogaerts J, Blay JY, Rare Cancers Europe Consensus P. Rare Cancers Europe (RCE) methodological recommendations for clinical studies in rare cancers: a European consensus position paper. Annals of oncology : official journal of the European Society for Medical Oncology / ESMO. 2015;26:300–306.
64. Dooms M, Saesen R, Steemans I, Lansens J, Huys I. Characteristics of Early Phase Clinical Trials for Rare Cancers: Insights From Interviews With Stakeholders. Front Pharmacol. 2022;13:775217. [PubMed: 35586057]
65. Brown J, Naumann RW, Brady WE, Coleman RL, Moore KN, Gershenson DM. Clinical trial methodology in rare gynecologic tumor research: Strategies for success. Gynecologic oncology. 2018;149:605–611. [PubMed: 29699802]
66. Blay JY, Coindre JM, Ducimetiere F, Ray-Coquard I. The value of research collaborations and consortia in rare cancers. The lancet oncology. 2016;17:e62–e69. [PubMed: 26868355]
67. Hanna MG, Reuter VE, Samboy J, et al. Implementation of Digital Pathology Offers Clinical and Operational Increase in Efficiency and Cost Savings. Arch Pathol Lab Med. 2019;143:1545–1555. [PubMed: 31173528]
68. Administration UFaD. Framework for FDA's Real World Evidence Program2018.
69. Cobb AN, Janjua HM, Kuo PC. Big Data Solutions for Controversies in Breast Cancer Treatment. Clinical breast cancer. 2021;21:e199–e203. [PubMed: 32933862]
70. Bourla AB, Meropol NJ. Bridging the divide between clinical research and clinical care in oncology: An integrated real-world evidence generation platform. Digit Health. 2021;7:20552076211059975. [PubMed: 34868623]
71. Gurcan MN, Chan HP, Sahiner B, Hadjiiski L, Petrick N, Helvie MA. Optimal neural network architecture selection: improvement in computerized detection of microcalcifications. Academic radiology. 2002;9:420–429. [PubMed: 11942656]
72. Sahiner B, Petrick N, Chan HP, et al. Computer-aided characterization of mammographic masses: accuracy of mass segmentation and its effects on characterization. IEEE transactions on medical imaging. 2001;20:1275–1284. [PubMed: 11811827]
73. Dundar MM, Badve S, Bilgin G, et al. Computerized classification of intraductal breast lesions using histopathological images. IEEE Trans Biomed Eng. 2011;58:1977–1984. [PubMed: 21296703]

Author Manuscript Author Manuscript Author Manuscript Author Manuscript

74. Niazi MKK, Senaras C, Pennell M, Arole V, Tozbikian G, Gurcan MN. Relationship between the Ki67 index and its area based approximation in breast cancer. BMC cancer. 2018;18:867. [PubMed: 30176814]

75. Niazi MKK, Parwani AV, Gurcan MN. Digital pathology and artificial intelligence. The lancet oncology. 2019;20:e253–e261. [PubMed: 31044723]

76. Senaras C, Niazi MKK, Sahiner B, et al. Optimized generation of high-resolution phantom images using cGAN: Application to quantification of Ki67 breast cancer images. PloS one. 2018;13:e0196846. [PubMed: 29742125]

Author Manuscript Author Manuscript Author Manuscript Author Manuscript

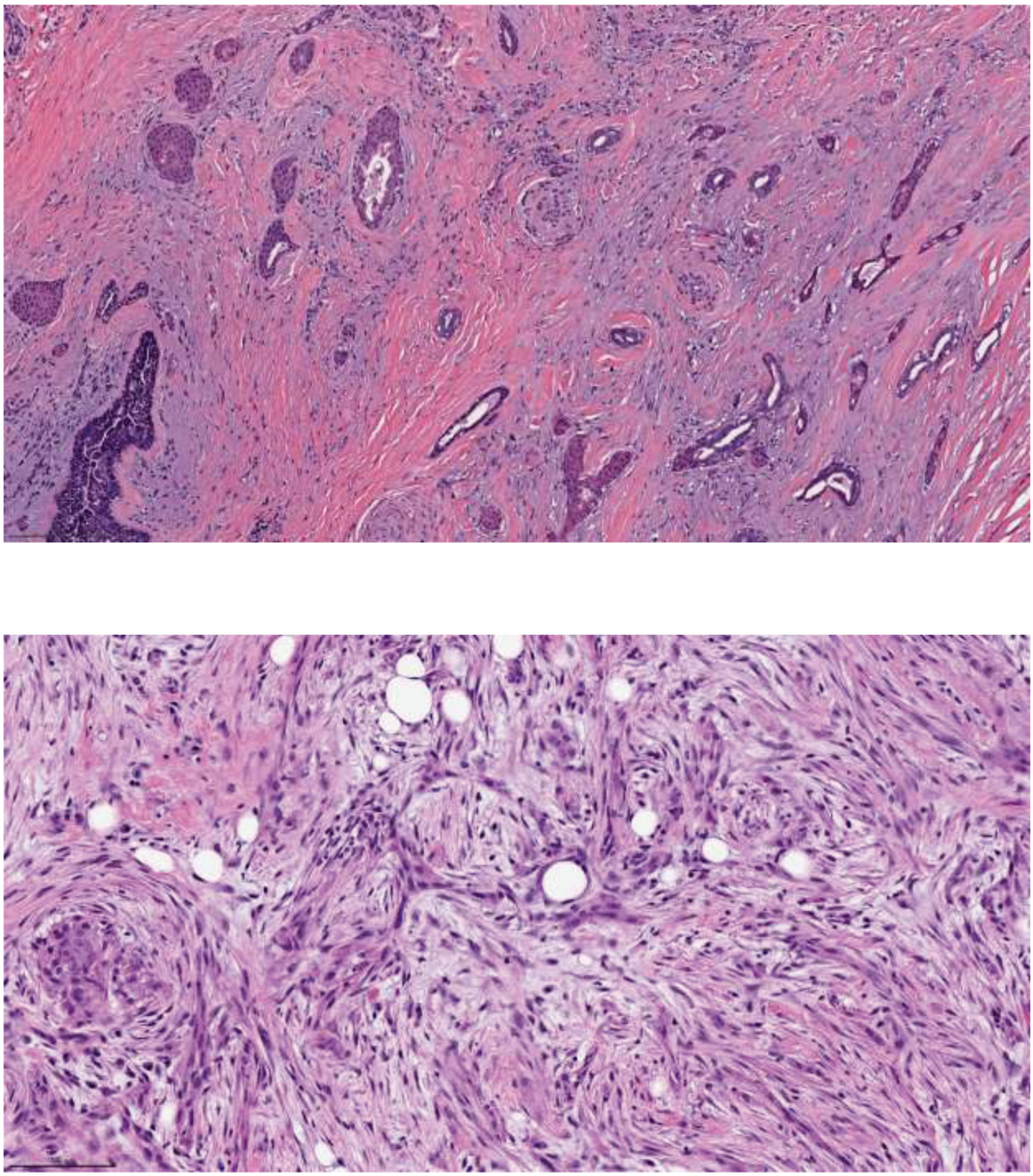

Figure 1.
Lower Risk Metaplastic Breast Cancer Histologies (a) Low-grade adenosquamous carcinoma (b) Fibromatosis-like metaplastic carcinoma

Author Manuscript Author Manuscript Author Manuscript Author Manuscript

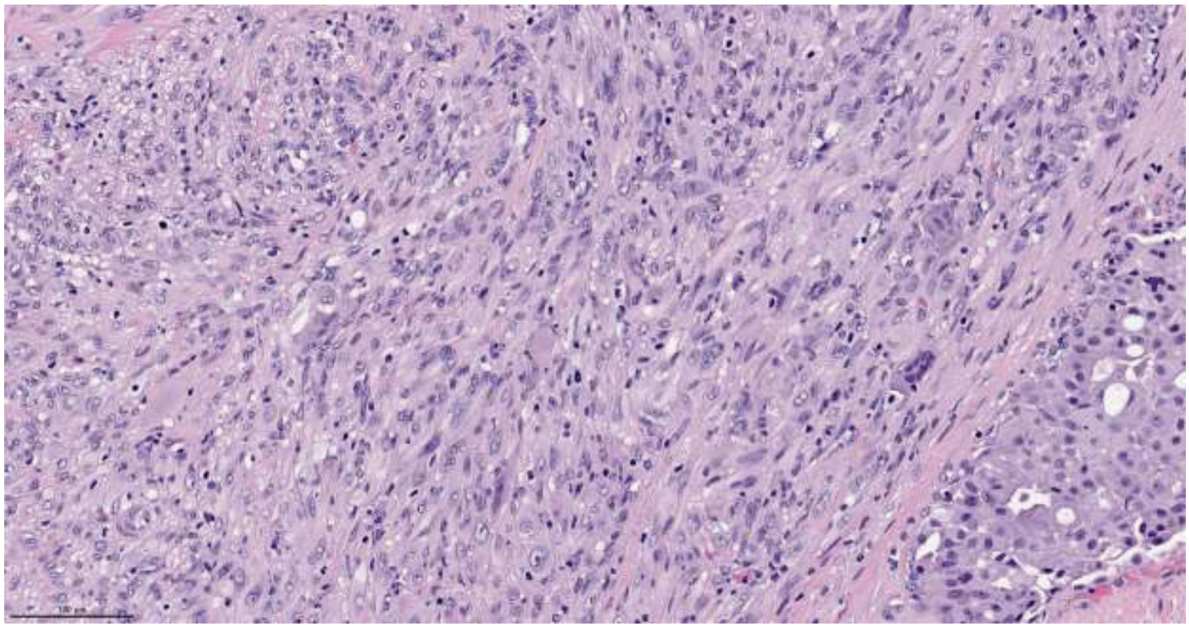

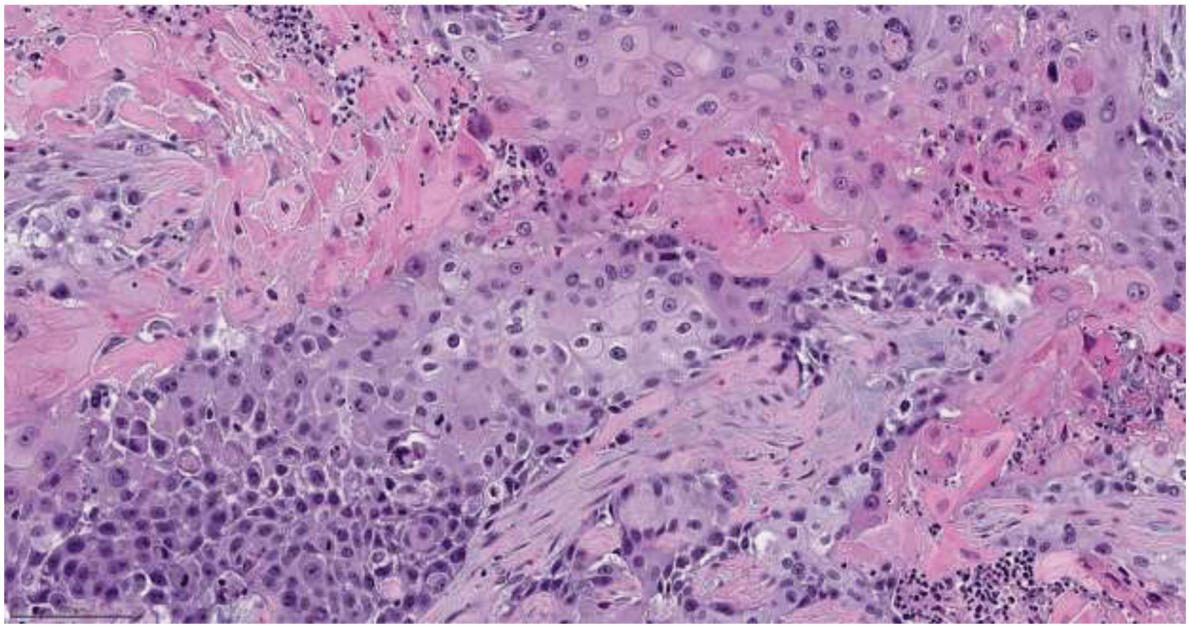

Author Manuscript Author Manuscript Author Manuscript Author Manuscript

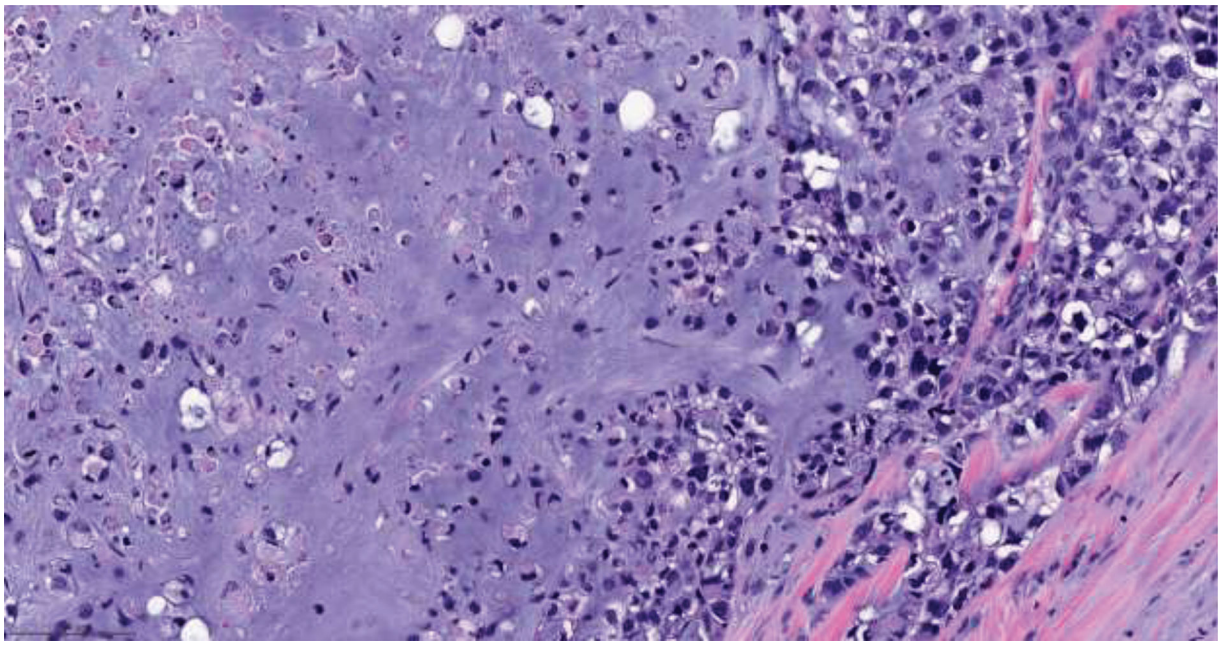

Figure 2.

Aggressive Metaplastic Histologies (a) Spindle cell carcinoma (b) Squamous cell carcinoma (c) metaplastic carcinoma matrix producing type

Author Manuscript Author Manuscript Author Manuscript Author Manuscript

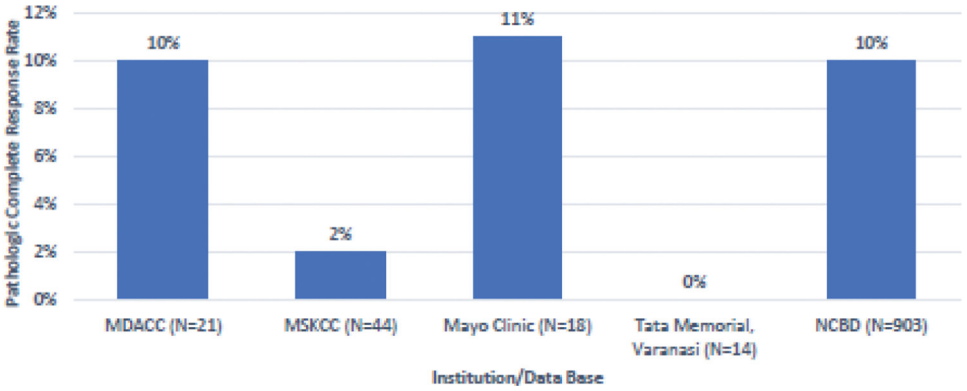

Figure 3.

Pathologic complete response rates to neoadjuvant therapy in single institution and database series.

Abbreviations: MDACC, MD Anderson Cancer Center; MSKCC, NCDB, National Cancer Database.

Author Manuscript Author Manuscript Author Manuscript Author Manuscript

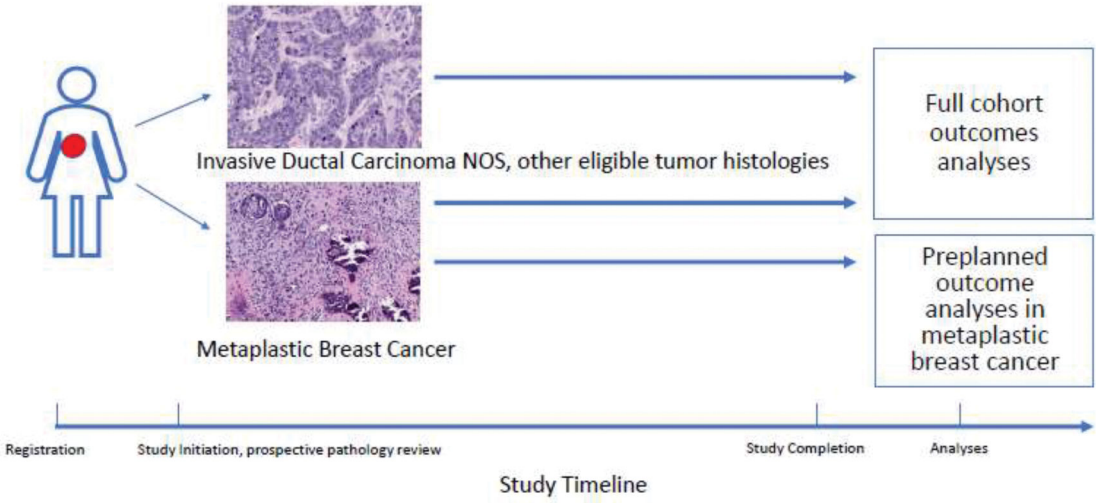

Figure 4.

Proposed schema for prospective identification of participants with metaplastic breast cancer entering onto clinical trials.

Author Manuscript Author Manuscript Author Manuscript Author Manuscript

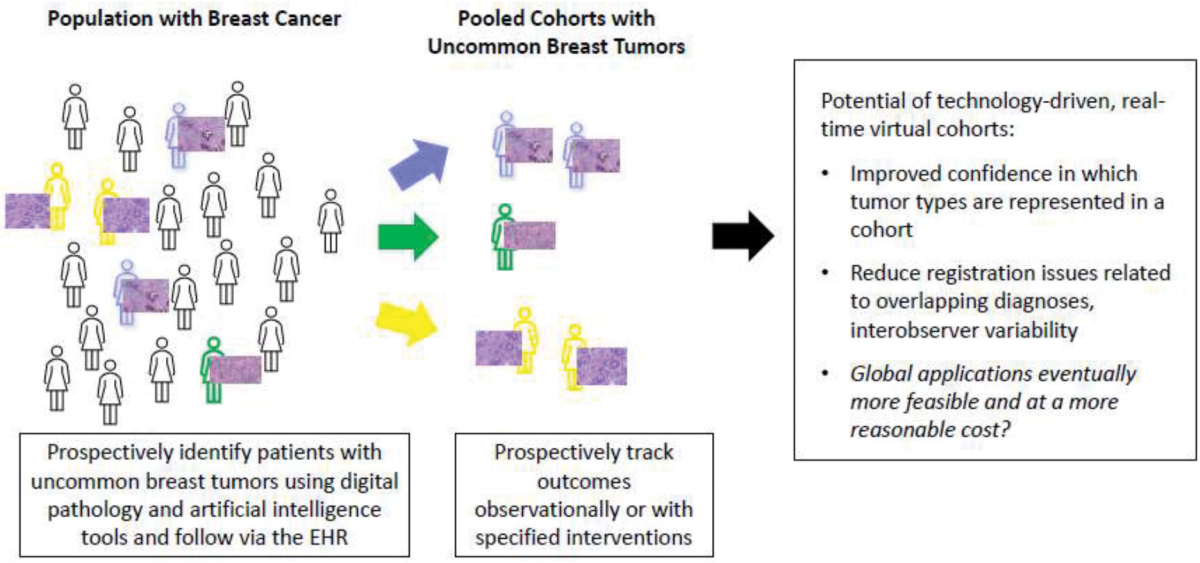

Figure 5.

Proposed schema for utilizing artificial-intelligence and digital pathology in the electronic health record to prospectively identify and group patients with uncommon breast tumors. Abbreviations: EHR, electronic health record

Author Manuscript Author Manuscript Author Manuscript Author Manuscript

Table 1 :

Frequency of Metaplastic Breast Cancer Presentations

Country	Data Source	Time Period	N	MBC (% of all breast cancer)	MBC (% of triple-negative breast cancer)	MBC % Stage IV at presentation
United States[6]	National Cancer Database	2004–2012	3,686	0.5%	3.9% *	2.7%
Korea[8]	Korea Central Cancer Registry	2002–2013	867	0.6%	--	--
Jordan[9]	King Hussein Cancer Center database	2005–2018	124	1.3%	--	9.7%
Brazil[10]	Instituto do Cancer do Estado de Sao Paulo	2009–2020	71	--	--	5.6%
Pakistan[11]	Aga Khan University Hospital cancer registry and Health Information and Management System	2008–2013	42	1.9%	--	9.5%
Italy[12]	TNBC Database (Four oncology units in Sardinia)	1994 – 2015	42	--	4.4%	--
India[13]	Tata Memorial, Varanasi	2019 –2022	28	--	--	7.1%
Iran[14]	Shiraz Breast Cancer Registry	2002- --	26	0.8%	8.5% *	--

Abbreviations: MBC, metaplastic breast cancer; --, not reported; TNBC, triple-negative breast cancer

*Includes all metaplastic tumors regardless of receptor status

Author Manuscript Author Manuscript Author Manuscript Author Manuscript

Table 2:

Reports of Exceptional Responses in Metaplastic Breast Cancer

Class	Novel Agent(s)	MBC Subtypes Described	Responses Described
Immunotherapy and immunotherapy combinations	Durvalumab, pembrolizumab, nivolumab, ipilimumab	Spindle cell (N=2), Chondromyxoid (N=1)[53]; Mesenchymal components and osseous differentiation[55] Squamous cell subtype[56]	Prolonged disease control in metastatic disease
PARP Inhibition with deleterious germline BRCA mutations	Talazoparib	Metaplastic chondrosarcomatous carcinoma[57]	Pathologic complete response with single agent neoadjuvant therapy
Anti-angiogenesis	Apatinib	Spindle cell breast carcinoma[58]	Prolonged disease control in metastatic disease
Pathway Inhibition	Buparlisib	Osteoid metaplastic breast cancer[59]	Prolonged disease control in metastatic disease
BRAF inhibition/MEK inhibition combination	Dabrafenib and Trametinib	Metaplastic carcinoma with melanocytic differentiation; BRAF mutation present[60]	Partial response and symptom control for one cycle in advanced disease

Abbreviations: MBC, metaplastic breast cancer; PARP, poly-ADP ribose polymerase